

## CASE CONFERENCE

# Suspecting the unexpected

Lyn CLEARIHAN

*Mt Evelyn Medical Surgery, Mt Evelyn, Victoria, Australia*

Mr B is a 75-year-old widower of Caucasian origins whom you have looked after for many years. His main problem has been depression and mild to hypertension moderate. He had smoked a pipe for many years and also suffered with slowly evolving cataracts. On his last routine eye examination he was noted to have asymmetrical optic discs and a visual field defect.

### **Q.1 What diagnostic options are you entertaining?**

In thinking about the cause of this type of problem it is useful to consider local problems and systemic causes:

- Local – chronic glaucoma
- Systemic – intracerebral pathology.

In addition to this, given the patient's age it would be important to exclude diabetes.

### **Q.2 How would you test for these?**

The diagnosis of glaucoma requires:

- an examination of the patient's fundi, looking for an alteration in the cup to disc ratio;
- an assessment of the intraocular pressures, which should be less than 20 mmHg;
- an assessment of the visual fields, where alteration in the peripheral fields may be noted.

As well as performing a full ophthalmology examination, a complete central and peripheral nervous system examination should be undertaken and a fasting blood glucose performed.

After a thorough examination of Mr B the only neurological abnormality noted was that he had a symmetrical hemifield quadrantic defect. His fasting blood glucose was normal and an assessment by an ophthalmologist established that his intraocular pressures were normal in both eyes and that the disc asymmetry was probably congenital.

### **Q.3 What would be your next step in this man's management?**

Due to the nature of the visual field defect, it is highly likely that a cerebral cause will be found. Mr B was thus referred for a computed tomography (CT) scan. This showed 'multiple areas of cortical infarction involving the right frontal and temporal lobes and a possible small infarct involving the left occipital lobe'.

### **Q.4 As this man is asymptomatic, does the CT scan explain his findings?**

The manifestation of a stroke is very dependent on which artery is involved and thus which areas of the brain are affected. Although occipital strokes may produce an homonymous hemianopia, the occipital infarction in this man would be strongly suspected as the cause of the visual field defect. Suspicion is also raised that the multiple cortical infarcts could be the underlying cause of his persistent depression.

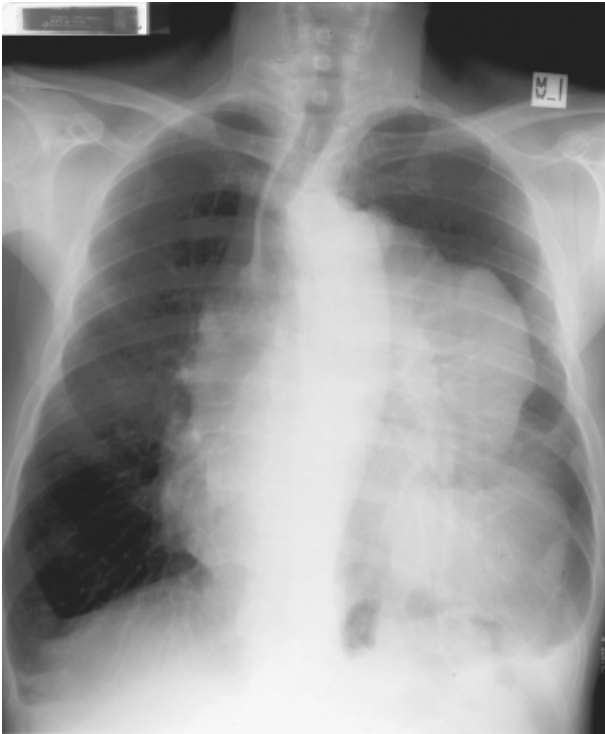
Mr B returns to see you with his CT scan result. You discuss this with him and commence him on low dose aspirin. As there is concern that an embolic cause for these multiple infarcts has not been ruled out, you explain that he will need to have a few more tests. You organize a blood screen, a chest X-ray and a carotid Doppler ultrasound. At this consultation you also discuss the importance of Mr B ceasing his smoking, which has been much heavier over recent years. You agree to discuss this further on his next visit.

### **Q.5 The radiologist rings you about the chest X-ray. What does it show?**

The X-ray (Fig. 1) shows a large irregular mass lesion arising from the region of the left hilum and distorting the cardiac outline and mediastinal contours. The mass is displacing the mediastinum and heart partly into the right hemi thorax.

---

Correspondence: Lyn Clearihan, Mt Evelyn Medical Surgery, 27 Hereford Rd, Mt Evelyn, Victoria, 3796, Australia.  
Email: lyn.clearihan@bigpond.com



**Figure 1** Mr B's chest X-ray.

***Q.6 What are the possible causes of this finding and how will a definitive diagnosis be made?***

The appearance of the X-ray puts a malignancy high on the list of differential diagnoses. In particular, a central bronchogenic carcinoma or possibly a lymphoma. Making a tissue diagnosis is very important and thus referring the patient for a lung biopsy would be the next step. This was undertaken and gave the histological diagnosis of a neurofibrosarcoma. These rare tumors, unfortunately carry a poor prognosis and in Mr B's case the tumor proved to be non-resectable and unsuitable for radiotherapy or chemotherapy. He is currently receiving palliative care at home.

### **Acknowledgment**

Thank you to Dr. Anthony Palmer for permission to use this X-ray and for advice on this case presentation.